

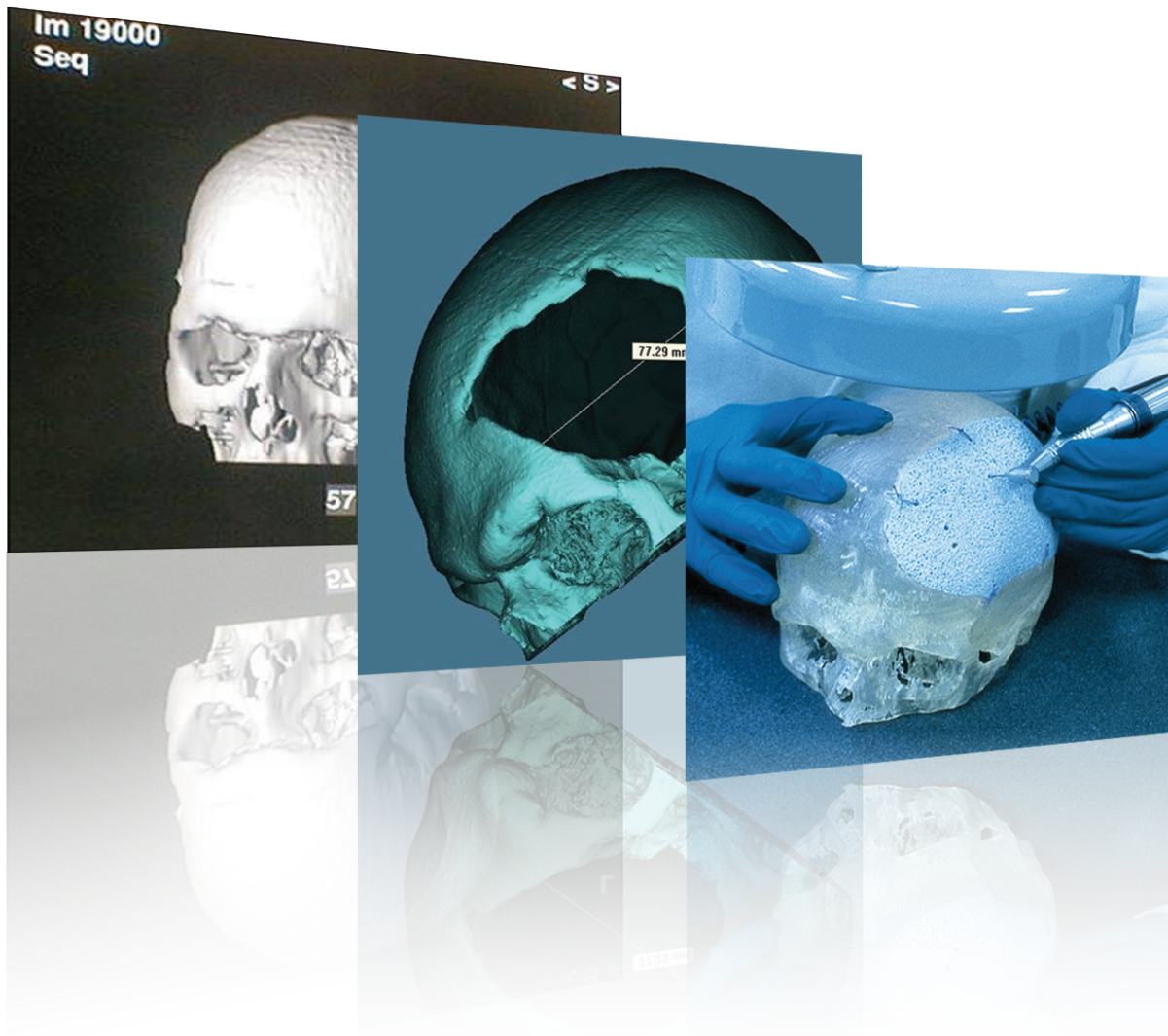
Customized **Bone**
Service

Patient specific hydroxyapatite implant



Biomimetic cranial
reconstruction



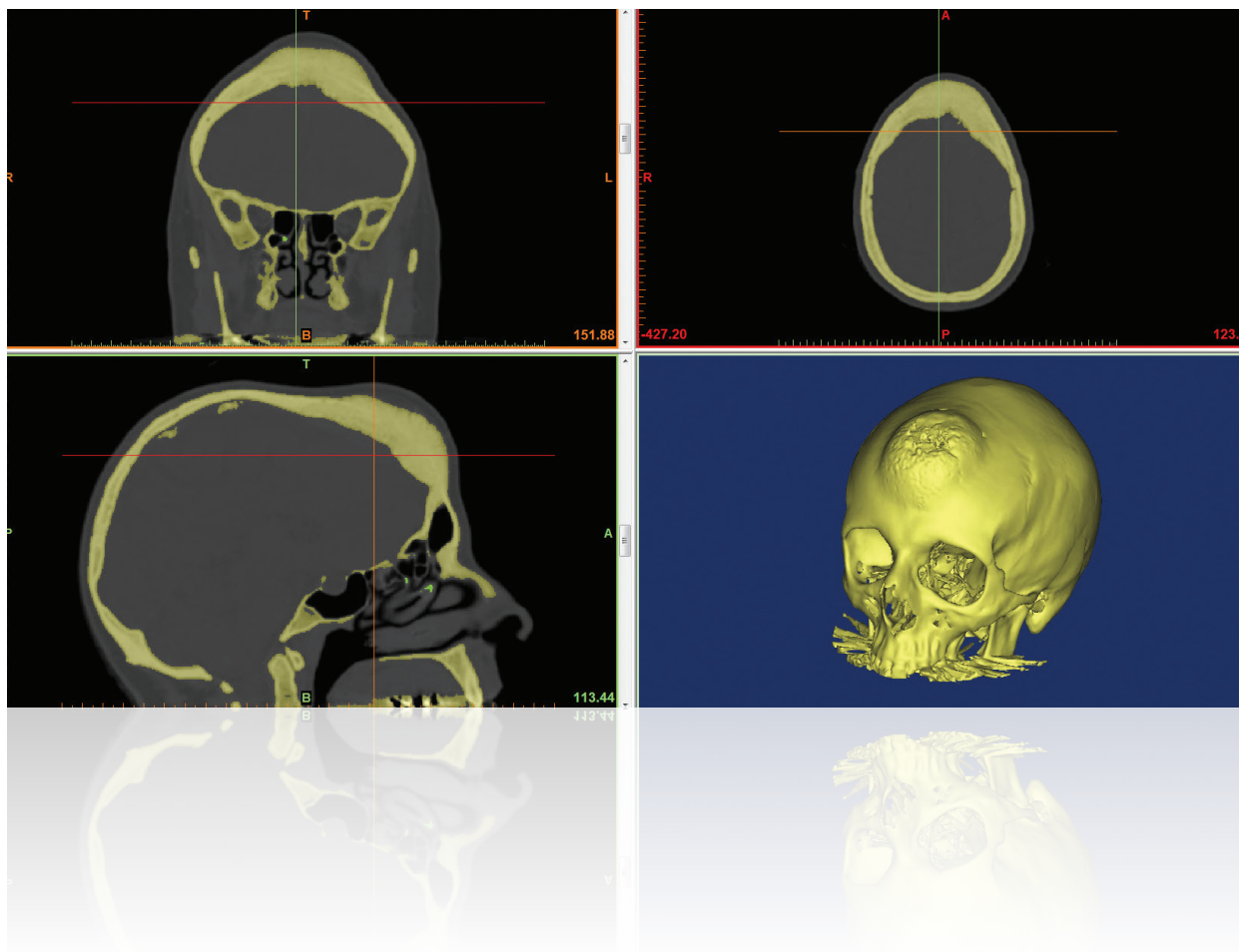


Cranial reconstruction

Today, the reconstruction of large and complex cranial defects is no longer considered simply a matter of the aesthetics. Neurological and psychological side effects must also be taken into account.

Through use of an advanced and bio-mimetic ceramic material, CustomizedBone Service provides a proven solution for bone replacement.

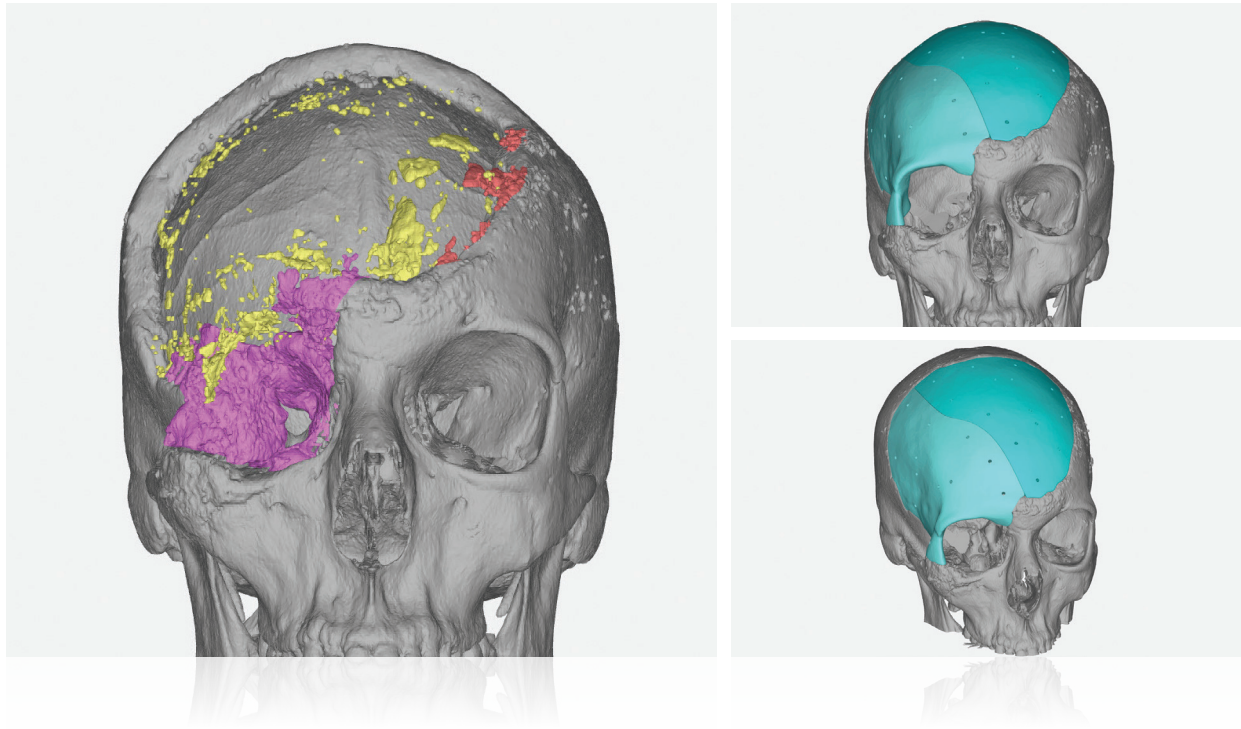
From the CT scan to the customized implant



Acquisition and elaboration of the CT scan

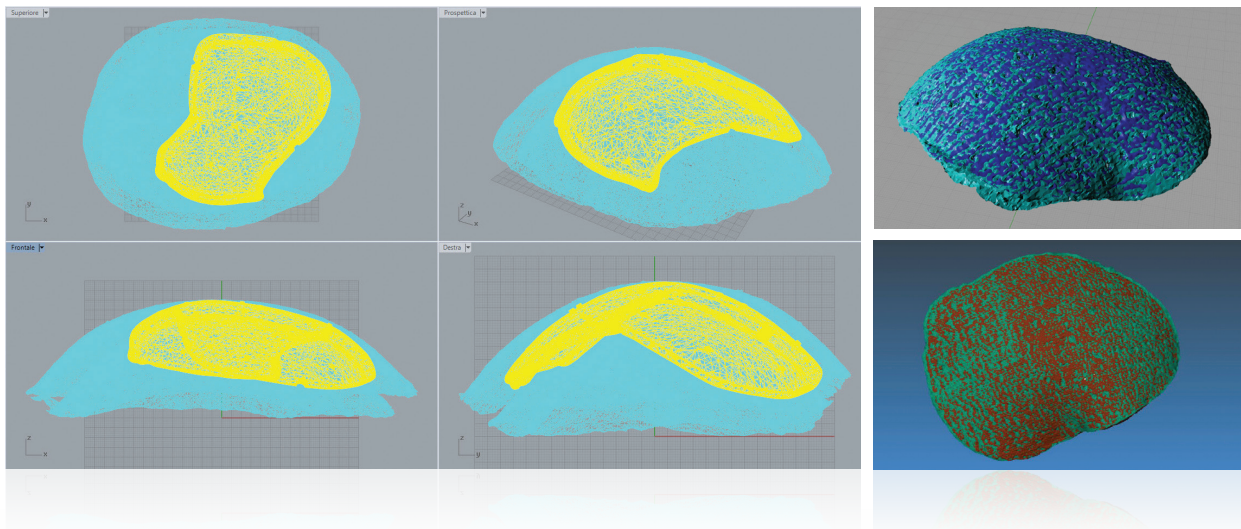
CustomizedBone Service starts from the raw digital data obtained during the CT scan, and through extensive computer elaboration, allows the creation of an individualized 3D computer reproduction of the patient's skull.

A detailed protocol providing all the necessary parameters for correct 3D data acquisition is provided through the CustomizedBone Service web portal.



3D model direct discussion with the surgeon

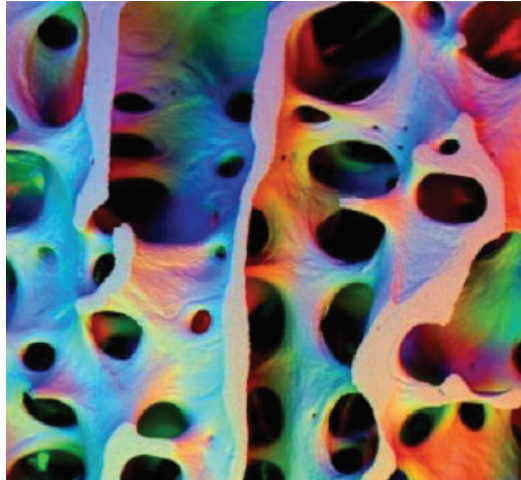
Together with "Finceramica's team", the surgeon has the opportunity to discuss and review the patient specific device design through CustomizedBone Services's web portal ordering platform. This is a crucial phase in order to provide an individually tailored designed implant for patient.



From design to realization


Once the design has been approved by the surgeon, the high tech manufacturing process starts, leading to a highly crystalline hydroxyapatite prosthesis. Implants are supplied sterile, ready for surgery.

The importance of bio-mimetic materials



Natural Bone

≈



Porous hydroxyapatite

In modern medical science, the concept and application of bio-mimetic materials has been consolidated and incorporated into everyday clinical practice. These bio-mimetic materials are defined as synthetic materials with a chemical composition and structure that resembles the mineral component of human bones .

For CustomizedBone Service, the research team at Finceramica has transferred this concept into reality through the development of a bio-mimetic ceramic biomaterial based on macro and micro porous hydroxyapatite, a major (70%) component of human bone^{1,2}.

Specific bio-mimetic chemical composition combined with an elevated interconnected porosity play a role in the perimetral osteointegration process.

In particular CustomizedBone's interconnected macro-pores are suitable for housing cells responsible for bone regeneration^{3,4}. Based on CT studies, the implants demonstrate perimetral osteointegration^{3,5-9}.

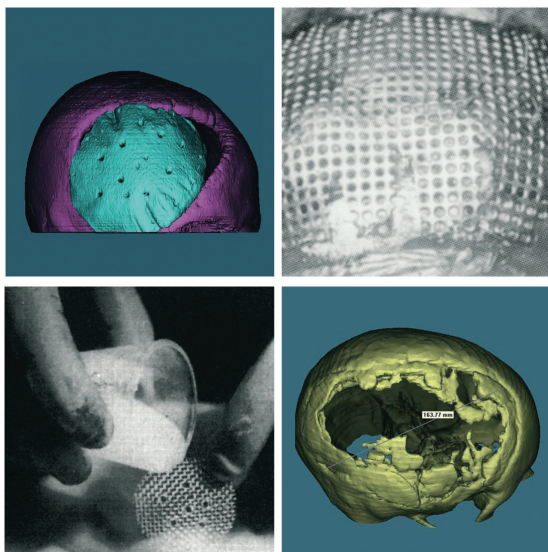
Manufacturing process featured by a high temperature sintering process, enhances highly crystalline non absorbable ceramic hydroxyapatite (HA).

- 1) Peyrin F, Mastrogiacomo M, Cancedda R, Martinetti R. "SEM and 3D synchrotron radiation micro-tomography in the study of bioceramic scaffolds for tissue-engineering applications". *Biotechnol Bioeng.* 2007 Jun 15;97(3):638-48.
- 2) Martinetti R, Dolcini L, Mangano C. 2005. Physical and chemical aspects of a new porous hydroxyapatite. *Anal Bioanal Chem* 381(3):634-638.
- 3) Lucia Martini, Guido Staffa, Gianluca Giavaresi, Francesca Salamanna, Annapaola Parrilli, Elena Serchi, Daniele Pressato, Elena Arcangeli, Milena Fini. 2012. Long-term results following Cranial Hydroxyapatite Prosthesis Implantation in a Large Skull Defect Model. *Plastic and Reconstructive Surgery.* 625-635
- 4) Maddalena Mastrogiacomo, Silvia Scaglione, Roberta Martinetti, Laura Dolcini, Francesco Beltrame, Ranieri Cancedda, Rodolfo Quarto. Role of scaffold internal structure on in vivo bone formation in macroporous calcium phosphate bioceramics. 2006. *Biomaterials*
- 5) Staffa G, Barbanera A, Faiola A, Fricia M, Limoni P, Mottaran R, Zanotti B, Stefani R. "Custom made bioceramic implants in complex and large cranial reconstruction: a two-year follow-up". *J Craniomaxillofac Surg.* 2012 Apr;40(3):e65-70.
- 6) Zaccaria L, SJ Tharakan, Altermatt S "Hydroxyapatite ceramic implants for cranioplasty in children: a single-center experience" *Childs Nerv Syst.* 2017 Feb;33(2):343-348
- 7) Fricia M, Passanisi M, Salamanna F, Parrilli AP, Giavaresi G, Fini M. "Osteointegration in Custom-made Porous Hydroxyapatite Cranial Implants: From Reconstructive Surgery to Regenerative Medicine" *World Neurosurg.* 2015 Aug;84(2):591.e11-6
- 8) Messina G, Dones I, Nataloni A, Franzini A. "Histologically demonstrated skull bone integration in a hydroxyapatite prosthesis in a human" *Acta Neurochir (Wien).* 2011 Aug;153(8):1717-8
- 9) Sprio S, Fricia M, Maddalena G, Nataloni A, Tampieri A "Osteointegration in cranial bone reconstruction: a goal to achieve" *J Appl Biomater Funct Mater* 2016; 14(4): e470-e476
- 10) Uchida A, Araki N, Shinto Y, Yoshikawa H, Kurisaki E, Ono K. The use of calcium hydroxyapatite ceramic in bone tumour surgery. *J Bone Joint Surg Br.* 1990 Mar;72(2):298-302.



The unique properties of bio-mimetic ceramic material

- biomimetic macro- and micro- porosity
- interconnected macro-pores are suitable for housing cells responsible for bone regeneration
- highly bio-compatible material, showing a reduced post-op infection incidence compared to titanium-based implants (*)
- the porous structure and hydrophilic surface allow for loco-regional use of antibiotics, when deemed clinically useful by the surgeon (**, ***)
- natural aesthetic result leading to high level of patient satisfaction
- completely radiolucent allowing for MRI diagnostics without artifacts



Limitations of other cranioplasty materials^{a,b,c}

Autologous bone:

- conservation procedures are complex
- limited material quantity which may not be sufficient for large and complex defects
- donor site morbidity
- potentially reabsorbed, especially in certain patient groups

Titanium and acrylic resins:

- not biomimetic materials
- not osteoconductive
- artifacts during diagnostic MRI

(*) Data consider both local and systemic infections, Lindner D, Schlohofer-Schumann K, Kern BC, Marx O, Müns A, Meixensberger J. Cranioplasty using custom-made hydroxyapatite versus titanium: a randomized clinical trial. J Neurosurg. 2017 Jan; 126 (1): 175-183.

(**) Nataloni A., Martinetti R., Staffa G., Servadei F. Rifamicine release from porous hydroxyapatite as anti-infection prophylactic for the cranial theca reconstruction. PROCEEDINGS 6th Meeting and Seminar Ceramics, Cells and Tissue, Faenza, p.198-201 (2000).

(***) Iaccarino C, Mattoño PP, Zanotti B, Bellocchi S, Verlicchi A, Viaroli E, Pastorello G, Sgulò F, Ghadirpour R, Servadei F. Septic complication following porous hydroxyapatite cranioplasty: prosthesis retention management J Neurosurg Sci. 2016 May 13.

a) Wang J. et al. Hunan Yi Ke Da Xue Xue Bao. 2002; 27 (2): 187.

b) Nakagawa S. et al. Neurol Med Chir 2003; 43 (3): 120-4.

c) Chen T.M. et al. Ann Plast Surg. 2002; 49 (3): 272-7.

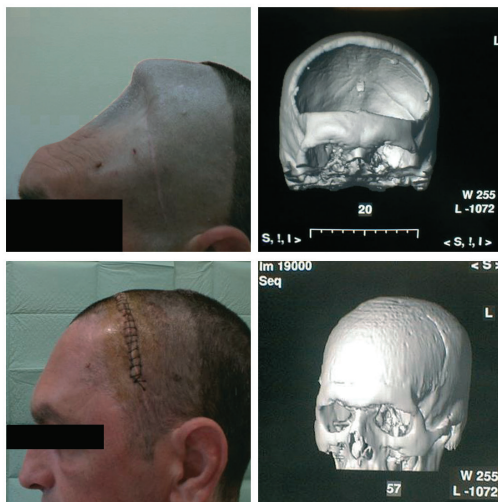Indications

CustomizedBone Service is indicated to replace bony voids in the cranial and/or craniofacial skeleton (frontal bone including the brow ridge).

This device is indicated for both adult and pediatric use (for children 7 years of age and above).

CustomizedBone implants are suitable for reconstructing cranial and/or craniofacial defects resulting from:

- trauma and vascular pathologies, either associated or non-associated to cranial decompression;
- removal of tumors;
- reabsorption of autologous bone;
- rejection of other prosthetic materials;
- congenital malformations.

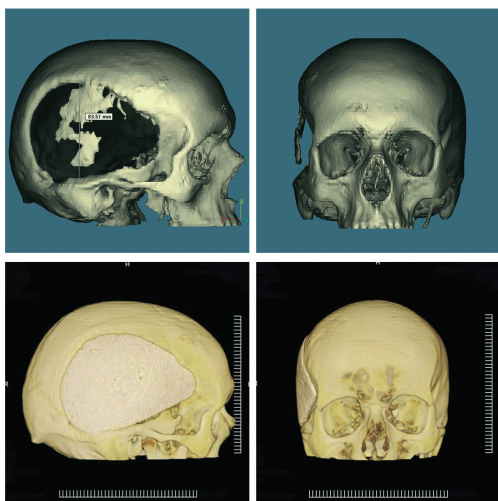


Example of bifrontal cranial reconstruction following trauma. Top: pre-op image of the cranial (left) and pre-op CTscan (right). Bottom: aesthetic result after cranioplasty (left) and post-op CTscan (right). *

Trauma

Patient presented a serious cranial trauma due to a car accident. A bilateral frontal decompression was performed and then, in a second operation, the cranioplasty was performed with CustomizedBone.

* Rivista Medica, Vol. 11, N. 3-4, Sept-Dec 2005.

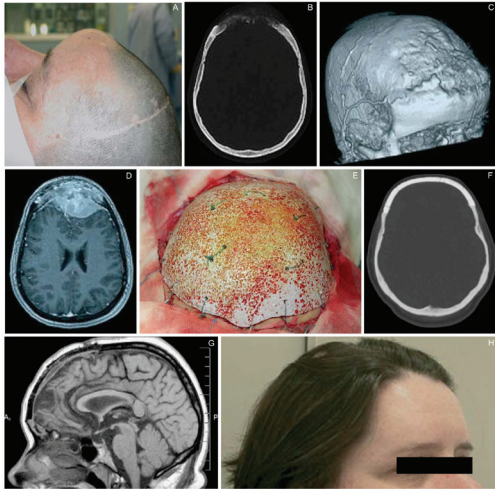


Reconstruction of parieto-temporal cranial defect due to autologous bone reabsorption. Top: lateral (left) and frontal (right) view of CTscan. Bottom: two-months followup CTscan, lateral (left) and frontal (right) view. *

Absorption of autologous bone graft

Seventeen-year-old patient presented absorption of the autologous bone graft after a craniotomy. The defect area was removed and the CustomizedBone prostheses implanted in a single operation.

* Rivista Medica, Vol. 11, N. 3-4, Sept-Dec 2005.

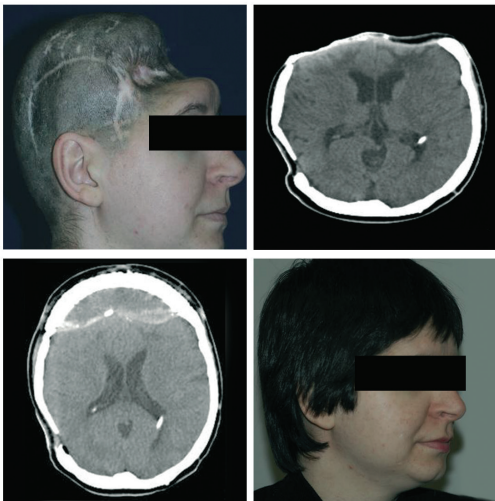


- A) Aesthetic aspect prior to surgery.
- B) Pre-op axial CT shows involvement and deconstruction of the bony plate.
- C) Pre-op 3D rendering based on cranial CT images.
- D) Pre-op axial contrast-enhanced MRI
- E) CustomizedBone cranioplasty implant in situ after neuronavigator-assisted Surgery. Post-op follow-up after two years: Axial cranial CT (F) and sagittal cranial MRI (G).
- H) Aesthetic outcome one year after neuro-navigator-assisted cranial demolition/reconstruction. *

Tumor resection

Demolition and resection of an atypical meningioma relapse at the forehead was performed on a 45-year old female patient. Cranial reconstruction with CustomizedBone implant was performed with one step procedure in combination with neuronavigational system.

* Topics in Medicine 2010; Special Issue 1-4.



Example of bifrontal post-traumatic reconstruction followup removal of previously applied resin cranioplasty. Top: pre-op image of the cranial defect (left) and pre-op CTscan (right). Bottom: post-op CTscan (left) after 8 months from surgery and final aesthetic result (right). *

Second line treatment following other material rejection

Patient underwent cranial decompression after trauma, reconstruction of the area was performed with a resin implant. An infection occurred and material was rejected. Final reconstruction was successfully performed using a CustomizedBone Service implant.

* Rivista Medica, Vol. 11, N. 3-4, Sept-Dec 2005.





Manufacturer:



Fin-ceramica faenza spa
manufacturing facility: via Ravennana 186 – 48018 Faenza RA, Italy
registered office: via Granarolo 177/3 – 48018 Faenza RA, Italy
t +39 0546 607311 – f +39 0546 607312
info@finceramica.it – www.finceramica.it